



Introduction

Local therapeutic strategies in breast cancer management are essential for patients with contraindications to surgical interventions. We explore the use of laser ablation, Photo-Dynamic Therapy (PDT), and Sonodynamic therapy (SDT) to ablate a superficial breast lesion, accompanied by metabolic optimization to improve treatment outcomes.

Methods

Case Presentation

TB is a 79-year-old woman with a previous history of open-heart surgery and an ejection fraction of 30%. She is hypertensive on beta blockers, a statin and insulin. In 2021, a persistent breast lump was felt, and a sonomammogram revealed a solid lesion in upper central aspect of the left breast (BIRADS-4c). An ultrasound guided core needle biopsy was performed, and pathology determined that the lesion was infiltrating ductal carcinoma Grade II with an immunohistochemistry of ER+, PR+, Her2- and Ki67 was 8%.

Metabolic baseline lab measures were:

- FBS 185 mg/dL, HBA1c 6.8%, IGF-1 87 ng/mL
- Homocysteine 23.9 μ mol/L, Vitamin D3 5 ng/dL !
- Uric acid 9 mg/dL
- Hb 9.7 with low MCV, Hct, MCH, MCHC & high RDW 16.5%
- IL-6 22 pg/mL

Multi-Modal Therapeutic Approach for Breast Lesion Ablation and Metabolic Modulation in a Postmenopausal Woman

Ahmed Elsakka MD, Nasha Winters ND FABNO, Deborah Kennedy ND PhD

Case presentation (cont'd)

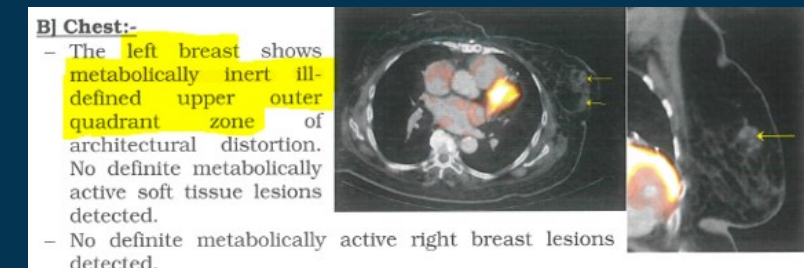
From a conventional oncology treatment perspective, she was not a surgery candidate due to her advanced age and heart condition. However, from a metabolic/ integrative approach there were options.

Systemic therapies implemented

- Intravenous leucovorin injection 100mg vial over 24 hours for 10 days followed by compounded methylation support capsules (methyl folate 400mcg, methyl cobalamin 500mcg, riboflavin 25 mg, betaine anhydrous 700 mg) bid (avoid B6 due to transsulfuration pathway)
- LDN, titrated dose from 1.5 mg to 4.5 mg, daily
- Low glycemic index, low methionine diet alternating with ketogenic diet according to homocysteine level
- metformin 1000 mg, statin 40 mg
- Vitamin D3 supplementation

Custom compounded supplements

- Liposomal curcumin, 250 mg qd
- Liposomal acriflavine (HIF1 inhibitor) 10 mg bid
- Liposomal chrysin + DIM



Sonographic examination confirmed the mammographic findings and revealed left breast ill defined complex cystic lesion measuring about 1.8 X 1.2 cm at 12 O'clock, 3 cm from the nipple with internal soft tissue lesion measuring about 1 X 0.9 cm, with no internal vascularity.

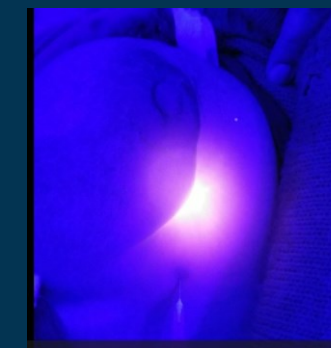


Image of Ultrasound guided Photo-Dynamic therapy

Loco regional therapy

Since there was a single, < 2 cm lesion, that was superficial, not adherent to the chest wall and in proximity to the nipple areola and skin; she was offered a single intra-lesion laser ablation, 4500-8000 J/cm³ and local PDT to ablate the main feeding vessels and reduce the risk of fat necrosis. A follow-up dynamic breast MRI confirmed that the normal breast vascularity had not been affected. Eight sessions of local superficial photo-sonodynamic therapy with sensitizing agents was performed to address the peri-tumoral vasculature. These treatments were followed with a PET scan and dynamic breast MRI to confirm remission (see above).

Results/Discussion

The multi-modal approach demonstrated several positive outcomes:

- Successful laser ablation with minimal impact on vasculature.
- Improved tumor targeting and efficacy through PDT and SDT.
- Metabolic optimization led to significant improvements in various biomarkers:
- FBS dropped to 130 mg/dL, homocysteine to 12.5 μ mol/L.
- IL-6 levels went to 8 pg/ml, while vitamin D and hemoglobin levels were markedly improved.

Conclusion

This case demonstrates the feasibility and benefits of integrating laser ablation, PDT and SDT with personalized metabolic treatment in managing breast lesions in challenging patients. The approach presents a novel avenue for advancing non-surgical treatments for localized breast tumors, offering an alternative for patients with complex medical histories. Further investigations are warranted to validate the efficacy and generalizability of this multi-modal approach.